

Dental Case Study

Dentigerous Cyst in a Pug

Webster Groves
Animal Hospital

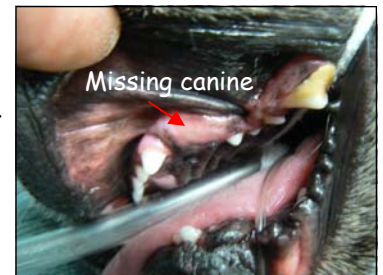Issue 3

May 2010

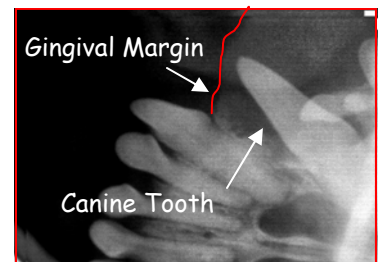
A five-year-old pug presented for annual wellness exam and vaccines. The dog was doing well and the owner had no concerns. It was noted that the dog's left maxillary canine was not present and there was a soft fluid pocket at its normal location (Pic. 1). A dental cleaning with radiographs was recommended and scheduled for the following week. Radiographs showed the missing canine under the gingival margin and a radiolucent area around the canine that affected the third incisor and the first three premolars. (Rad.1 and Pic. 2) Because of the lack of bone support for

the third incisor, canine and first three premolars, those teeth were extracted. The lining of the cyst was removed and the gingiva closed in a simple interrupted pattern.

Dentigerous cyst is a fluid-filled cyst surrounding the crown of an unerupted tooth. The cyst will continue to grow and cause bone loss to surrounding teeth until treated by removal of the cystic lining. These cysts can eventually lead to a fractured mandible, oral-nasal fistula, and considerable tooth loss.



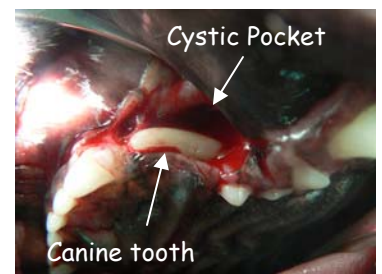Picture 1



Radiograph 1

Things To Remember

- Dentigerous cysts develop from unerupted teeth but not all unerupted teeth will develop a dentigerous cyst.
- Dentigerous cysts can be prevented by early removal of unerupted teeth, if a dog or cat is missing teeth on exam a dental with radiographs is recommended.
- Boxers are predisposed to supernumerary incisors (especially uppers) and first premolars (uppers). So if a normal amount of teeth are seen but a gingival swelling is noted there is still a chance of dentigerous cyst.
- It is important to have your pet's teeth routinely examined. Please call our office at 314-968-4310 to schedule an appointment or to answer questions you may have about your pet's dental health. Thank you, Michael Balke, D.V.M.



Picture 2